

CHRONIC UTERINE INVERSION ASSOCIATED WITH FIBROID - A CASE REPORT

J. K. Goel¹, Shanti Sah², Shashi Bala Arya¹, Ruchica Goel³, Nandini Agarwal⁴

Publication Info

Paper Submission Date
18th October 2016

Paper Acceptance Date
19th November 2016

Paper Publication Date
December 2016

DOI
10.21761/jms.v1i2.7358

Abstract

Introduction: Uterine inversion is a condition in which the uterus turns inside out with prolapse of fundus through the cervix into or outside vagina. Chronic inversion cases are rare. We present a rare case of chronic uterine inversion associated with uterine fibroids.

Case Report: A 42 year old female, P₃L₃, was admitted with complains of menorrhagia & pain lower abdomen for 1 month. Speculum examination revealed a fleshy polyp filling whole of vagina. On per vaginal examination size of mass could not be assessed and cervical lips could not be felt. So, a provisional diagnosis of fibroid polyp was made. Per-operatively inversion of tube and ovaries along with a sessile submucosal fundal fibroid polyp of size 10 x 8 cm was found. A revised diagnosis of chronic uterine inversion with sessile fibroid polyp was made. Patient then underwent Total Abdominal Hysterectomy with Bilateral Salpingo-oophorectomy.

Conclusion: Chronic inversion should be kept as a differential diagnosis in a patient with history of irregular bleeding associated with dragging pain of lower abdomen and feeling of a mass coming out of introitus. Pre operatively it should be differentiated from fibroid polyp, uterine prolapse & prolapsed hypertrophied ulcerated cervix.

Keywords: Fibroid polyp, Uterine inversion, pelvic pain, menorrhagia.

INTRODUCTION

Uterine inversion is a condition in which the uterus turns inside out with prolapse of fundus through the cervix into or outside vagina.¹ Inversion of uterus can be acute which follows mismanaged 3rd stage of labour or it can be chronic. Incidences of chronic inversion are very rare & its incidence is 1 in 3500. We present a rare case of chronic uterine inversion associated with uterine fibroids.

CASE HISTORY

A 42 year old female, P₃L₃, was admitted with complains of increased flow during menses & pain lower abdomen for 1 month. Pain was dull in nature, constant with dragging sensation in lower abdomen. She also had history of fullness in vagina for last 1 month. She had history of 2 blood transfusions in the past for the above complaints. Her present cycles were of 10-12 days occurring at regular interval with passage of clots and associated with pain. On general physical examination, patient was pale with pulse, 82/min & BP 160/104 mm Hg. Abdomen was soft upon examination. Speculum examination revealed a fleshy

polyp filling whole of vagina, globular in shape, shaggy in appearance and bleeding present from the surface. On vaginal examination same mass was palpable whose exact size could not be assessed; cervical lips could not be made out. Bilateral fornices appears free. On per rectal examination, same mass palpable and rectal mucosa was free. Her haemoglobin was 9 gm% and ultrasound finding on admission revealed small size uterus with heteroechoic large mass of 91.6 x 91 mm posterior to uterus involving cervix and whole vagina and bilateral adenexa and ovaries normal suggestive of cervicovaginal polyp/mass. So a diagnosis of fibroid polyp was made & patient was planned for hysterectomy after improving her general condition. Per-operatively, there was cupping at fundal region and inversion of tubes and ovaries in it along with a sessile submucosal fibroid polyp of size 10 x 8 cm arising from uterine fundus. A revised diagnosis of chronic uterine inversion with sessile fibroid polyp was made and she was subjected to total abdominal hysterectomy with bilateral salpingo-oophorectomy. Post-operatively she had 1 unit blood transfusion and recovered well. Histopathology report suggestive of submucosal leiomyoma with red

Professor¹, Assistant Professor², Senior Resident³, Junior Resident⁴
Department of Obstetrics and Gynaecology, Shri Ram Murti Smarak Institute of Medical Sciences, Bareilly, Uttar Pradesh,
Corresponding Email : drjkgol309@gmail.com

degeneration. Large area of haemorrhage in uterine wall and ovary protruding out from the cervical os, consistent with the clinical diagnosis of Inversion of Uterus.

DISCUSSION

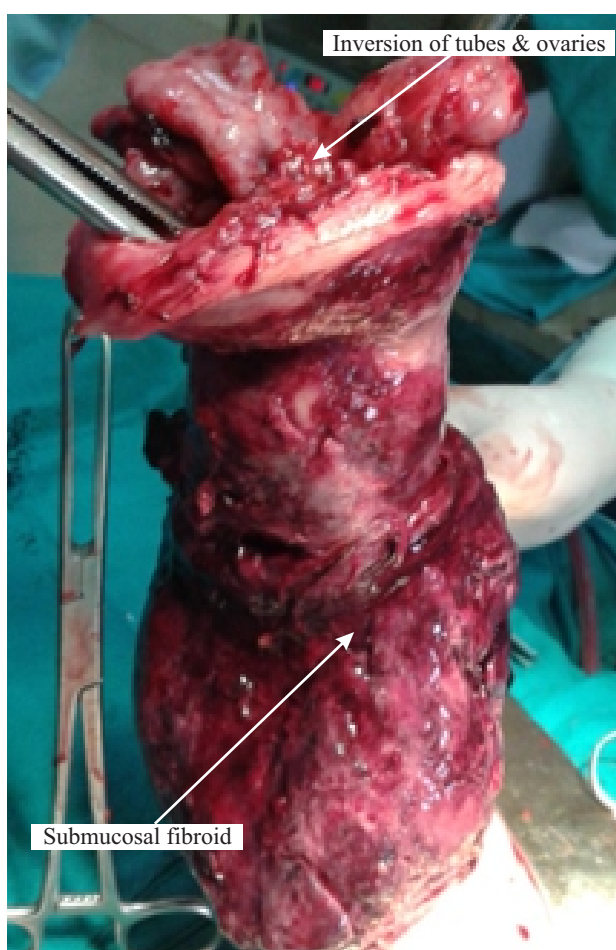
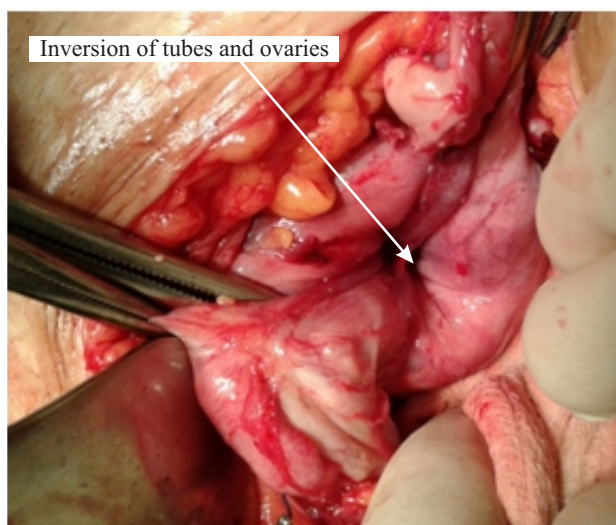
Non puerperal inversion of uterus is associated more frequently with older age group.² It usually follows an unnoticed or uncorrected post partum inversion³ or due to traction effect of submucous myomatous polyp arising from fundus or if a fundal fibroid undergoes sarcomatous changes causing softening of uterine wall due to infiltration of malignancy. The usual presenting symptoms are pain along with irregular vaginal bleeding and offensive vaginal discharge. Major factors causing uterine inversion when associated with fibroid are tumour attachment site, thickness of tumour pedicle, tumour size, thin uterine wall and dilatation of cervix.⁴ Diagnosis in case of chronic inversion is difficult and requires high index of suspicion specially when the inversion is partial.⁵ MRI scan detect an U-shaped uterine cavity, thickened and inverted uterine fundus on sagittal image and a “bull eye” configuration on an axial image as an indicative sign of uterine inversion.

CONCLUSION

Chronic inversion being a rare finding associated with fibroid uterus, it should also be kept in mind as a differential diagnosis when a patient with history of excessive or irregular bleeding associated with pain abdomen & feeling of a mass coming out of introitus or a dragging pain of lower abdomen. Pre operative it should be differentiated from fibroid polyp, uterine prolapse & prolapsed hypertrophied ulcerated cervix.

REFERENCES

1. D.C. Dutta's Textbook of Obstetrics, 8th Edition, pg 487
2. Kopal S, Seekin NC, Turhan NO. Acute inversion due to a growing submucous myxoma in an elderly woman: case report. EUR J Obstet Gynecol Reprod Biol. 2001;99:118-120
3. Rudra S, Naredi N, Duggal B.S., Seth A. Chronic Uterine Inversion: A Rare Complication of Mismanaged Labour. Med J Armed Forces India. 2010 Jan; 66(1): 91–92.
4. Lascarides E, Cohen M. Surgical Management of non-puerperal inversion of uterus. Obs. Gynecol 1968; 32:376-381



5. Takano K, Ichikawa Y, Tsunod H, et al. Uterine inversion caused by uterine sarcoma: a case report. Jpn Clin Oncol, 2001; 31(1):39-42